Non tuberculous mycobacteria related spondylodiscitis: a case report and systematic literature review

Alessandro Smimmo[1], Andrea Perna[1], Massimo Fantoni[2,3], Davide De Marco[1], Calogero Velluto[1], Luca Proietti[1,4], Michela Sali[2,5] , Francesco Ciro Tamburrelli[1,4]

[1]UOC Chirurgia Vertebrale, Fondazione Policlinico Universitario A. Gemelli IRCCS, Rome, Italy;
[2]Dipartimento di Scienze di Laboratorio e Infettivologiche, Fondazione Policlinico Universitario A. Gemelli IRCCS, Rome, Italy;
[3]Dipartimento di Sicurezza e Bioetica, Università Cattolica del Sacro Cuore, Rome, Italy;
[4]Istituto di Clinica Ortopedica, Università Cattolica del Sacro Cuore, Rome, Italy;
[5]Dipartimento di Scienze Biotecnologiche di Base, Cliniche Intensivologiche e Perioperatorie Sezione di Microbiologia, Università Cattolica del Sacro Cuore, Rome, Italy

SUMMARY

Purpose: Mycobacterium xenopi and Non Tuberculous Mycobacteria (NTM) are rare causes of spondylodiscitis (SD). The aim of this study was to highlight the relevance of considering these pathogens in differential diagnosis of slow growing SD, obtaining the correct diagnosis and evaluating the key points of management and therapy approach.
Methods: A case of surgically treated *Mycobacterium xenopi* SD is reported. A systematic review according to the Preferred Reporting Items for Systematic Reviews and Meta-Analyses (PRISMA) guidelines was performed. The research was conducted on MEDLINE, PubMed and Scopus using as search-terms "vertebral", "spinal", "infection", "spondylodiscitis", "discitis", "osteomyelitis", "atypical", "nontuberculous", "mycobacterium".
Results: After the screening of 444 titles and abstracts, 113 papers were considered eligible for the full-text analysis. Seventy-seven studies that met inclusion criteria were finally included in the review. Overall, including our report, 91 patients affected by NTM SD were analyzed in this systematic review
Conclusion: This review highlights the rarity of spinal infections due to NTM and the difficulty of their management. A tailored approach with prolonged antibiotic therapy, eventually associated with surgery in selected cases were suggested for the treatment of NTM infections.

Keywords: Mycobacterium xenopi, spondylodiscitis, vertebral osteomyelitis, non tubercolar mycobacteria, spinal infections.

INTRODUCTION

Spinal infections are severe conditions that require accurate procedures to reach diagnosis, often long-lasting antibiotic therapy and, sometimes, surgical treatment [1, 2]. Non Tuberculous Mycobacteria (NTM) infections are quite uncommon especially in healthy patients. However, lately, an increase of NTM-related infections was described in the Literature and 125 new species of NTM were reported [3]. NTMs could be implicated in many infections. The most common sites involved were the lungs, skin and joints; multiple organs involvement with disseminated infections could also occur [4]. Spondylodiscitis (SD) caused by NTM were rarely reported. Different species of NTM could cause SD, but the most frequent pathogens belong to the Mycobacterium Avium Complex (MAC) [5]. The *Mycobacterium xenopi* is an atypical, slow growing, scotochromogenic Mycobacteriium, firstly described in 1959 from skin le-

Corresponding author
Andrea Perna
E-mail: perna.andrea90@gmail.com

sions of an aquatic frog, *Xenopus laevis* [6]. *M. xenopi* is the third most common mycobacterium isolated from pulmonary specimens in Europe, less commonly isolated in the USA [7]. Extra-pulmonary infections caused by *M. xenopi* are rarely observed, also because of difficulties in the pathogen identification. The aims of the study were to report a rare case of *M. xenopi* SD in a patient with Systemic Lupus Erythematosus (SLE) and perform a systematic Literature review about Non Tuberculous Mycobacteria Spondylodiscitis (NTMSD) focusing on diagnostic and therapeutic difficulties.

MATERIAL AND METHODS

This research was conducted according to the Preferred Reporting Items for Systematic Reviews and Meta-Analyses (PRISMA) guidelines (Figure 1) [8].

Search Strategy

A systematic review of the Literature indexed in PubMed, MEDLINE and Scopus databases, using as search-terms: "vertebral", "spinal", "infection", "spondylodiscitis", "discitis", "osteomyelitis", "atypical", "nontuberculous", "mycobacterium" and their MeSH terms in any possible combination., using Boolean operator "AND" and "OR", was performed from 1970 to March 2020. The search was reiterated until May 15, 2020. The reference lists of relevant studies were screened to identify other studies of interest.

Inclusion and Exclusion Criteria

Were included in the present review studies reporting: demographic features, symptoms, diagnostic settings, treatment, possible complications and outcomes in patients with NTMVO. Only articles written in English with available abstract were included. Surgical technique reports, expert opinions, studies on animals, unpublished reports, cadaver or in vitro investigations, book chapters and abstracts from scientific meetings were excluded.

Data Collection

Two authors (A.P and A.S.) independently conducted the above mentioned search by title and abstract. If the articles met inclusion criteria, the full text was obtained and consequently reviewed. Any discordance was solved by consensus with a

Figure 1 - PRISMA Flow-chart.

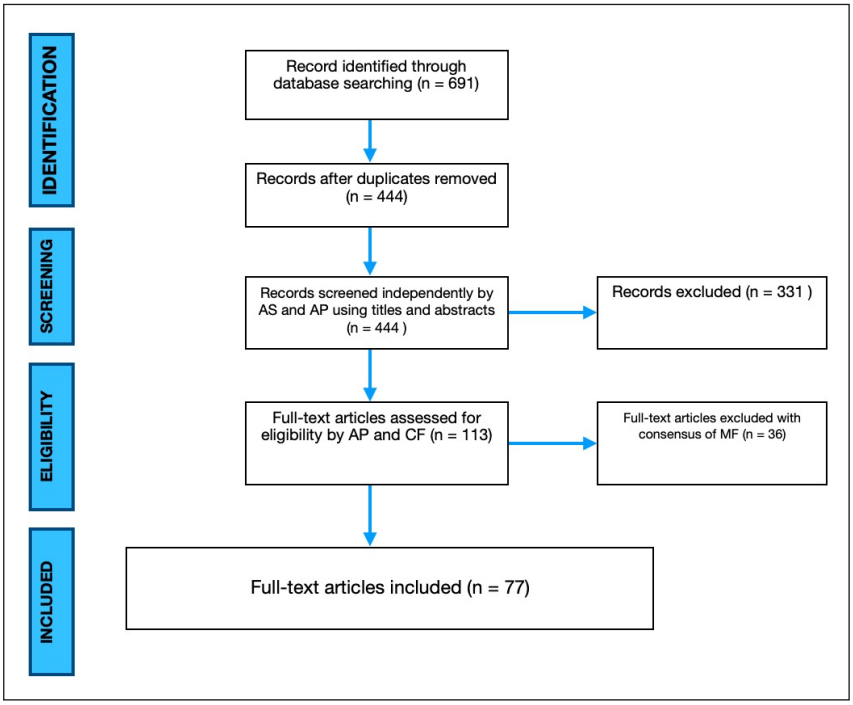

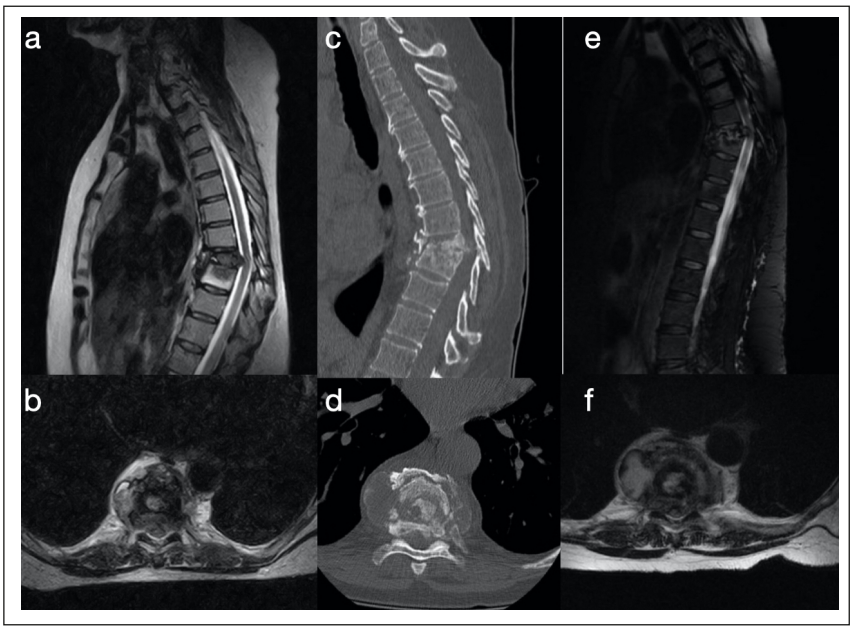

Figure 2
a,b. Spinal MR sagittal and axial images T2-weighted showing partial collapse of T8 vertebral body and hyperintensity of T8-T9 disc space suggestive for spondylodiscitis.
c,d. Spinal CT sagittal and axial images showing complete collapse of T8 and presence of spinal canal stenosis.
e,f. Spinal MR sagittal and axial images T2-weighted showing collapse of T8 vertebral body and spinal cord compression at T8-T9 level.

third author (M.F.). Items/data reported from the included articles were: age and gender of the patients, location of the NTMSD, type of surgical treatment performed, underlying conditions, presence and location of any abscesses, presence of any immunosuppressive therapy, antibiotic therapy used, duration of antibiotic therapy, outcome, complications, and duration of follow-up.

Statistical Analysis
Numbers software (Apple Inc., Cupertino, CA) was used to tabulate the obtained data. Categorical variables are presented as frequency and percentages. Continuous variables are presented as means and standard deviation. Only one decimal digit was reported and was rounded up.

CASE REPORT

In November 2019, a 46-year-old woman was admitted to our emergency unit for worsening back pain associated with bilateral legs weakness, urinary retention and walking deficit. The patient had an history of pyelonephritis of the right kidney, mitral valve insufficiency, focal crisis and aphasia, Systemic Lupus Erythematosus (SLE) for about 15 years, treated with prednisolone 10 mg daily. In January 2018 at another center, the patient was diagnosed with SD T8-T9 (Figure 2a, b). Computer Tomography (CT) guided percutaneous biopsy and postoperative blood-cultures were negative. Empiric antibiotic therapy was administered with a combination of vancomycin ev and teicoplanin ev for 14 days followed by administration of cefditoren per os up to September 2018. After treatment the patient reported a slight pain improvement.
In the emergency room a neurological examination was performed; no motor deficit of upper limbs was observed. Hypoaesthesia at T7-T8 territories, hypoaesthesia and motor deficit at lower limbs (3/5 MRC in hip flexion, leg extension, ankle flexion and extension) were found; patellar reflex were hyper-evocable bilaterally, Achilles reflex was absent bilaterally. Visual Analogue Scale (VAS) for back pain was 8. Laboratory test showed Erythrocyte Sedimentation Rate (ESR) of 27 mm/h, increased C-reactive protein (CRP 49.7 mg/L), Hb 13.1 g/ dL, White Blood Cells (WBC) 7.55x10^9/l.
A dorsal spine CT scan was performed and showed total collapse of T8 body with stenosis of spinal canal and swelling of paravertebral tissue (Figure 2 c, d). There was suspicion of slow growing mycobacteria spine infection therefore a spinal Magnetic Resonance Imaging (MRI) was performed and a spinal cord compression at T8-T9 was evident. At the same level, a complete col-

lapse of T8 body (Figure 2 e, f) morphological alteration, associated with stenosis of the spinal canal and were observed. Angular kyphosis due to the collapse of T8's body was also noted; segmental kyphosis was 34.9°. A soft inflammatory tissue was observed at the T8 body. Due to the worsening neurological symptoms decompressive surgery was required. Under general anesthesia and in prone position a debulking of purulent material associated with T8-T9 wide decompression through bilateral laminectomy, and T5- T12 trans-pedicle screw fixation was performed (Figure 3 a, c, d). During the surgery a correction of angular kyphosis was obtained. The thoracic Kyphosis changed from 34.9° preoperative to 16.5° postoperative (Figure 3 b, c). A large sampling of material was obtained during the surgery and sent for histological and microbiological analysis. After surgery empiric antibiotics therapy with Vancomycin 1000 mg every 12 h and Ciprofloxacin 400 mg every 12 h was started. A rigid brace was also prescribed for early mobilization. The exam on intraoperative sample resulted negative for fungi (cultural exam), yeasts (mass spectrometry), molds (mass spectrometry); moreover post-operative blood culture tests were all negative for microbiological growth. Histological analysis revealed a granulomatous inflammation. Quantiferon test was negative and after the decompressive surgery neurological symptoms significantly improved and the patient started to be mobilized. Laboratory indexes showed a decreasing trend CRP< 20 mg/L) and the pain was significantly decreased (VAS-back <2; VAS-legs <1). After one week the patient was discharged in good clinical and neurological conditions. Oral empiric antibiotic therapy was prescribed (Ciprofloxacin 500 mg cpr OS every 12 hours; Minociclin 100 mg every 12 hours). After 37 days cultural exams of intraoperative samples were positive for *Mycobacterium xenopi*. The molecular system used on the direct sample to differentiate *NTM* to *MTB* was Anyplex MTB/NTM real-time detection assay (Seegene).

The samples obtained by biopsy were used to grow mycobacteria in Lowenstein-Jensen (LJ) solid medium and BBL MGIT liquid medium (Becton Dickinson Diagnostic Systems). MGIT tubes were inoculated with 0.5 ml of the specimens and incubated in the MGIT 960 system at 37°C. Smears were prepared for microscopic examination by Ziehl-Neelsen staining and findings were compared with the results of culture, which was considered the standard diagnostic assay.

Once the microbiological diagnosis of *M. xenopi* infection was obtained, specific antibiotics therapy with ethambutol 800 mg/die os, rifabutin 300 mg/die os and azithromycin 500 mg/die os com-

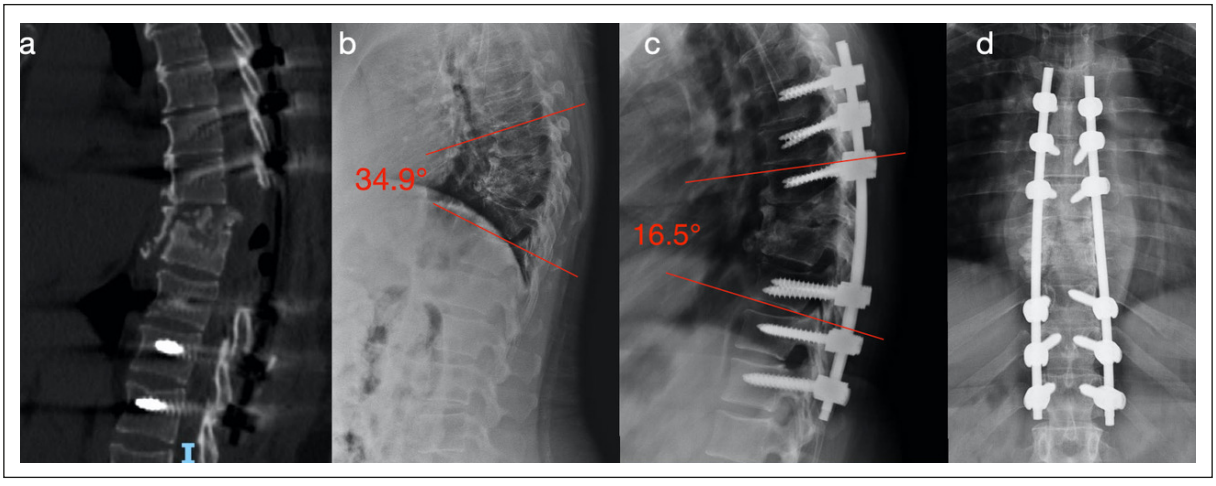

Figure 3.
a. Postoperative sagittal CT image showing deformity correction and wide decompression performed.
b. Preoperative standard X-Ray of thoracic spine in lateral view showing angular kyphosis of 34.9° between T7-T10 level.
c. Postoperative standard X-Ray of thoracic spine in lateral view showing angular kyphosis correction.
d. Postoperative standard X-Ray of thoracic spine in anteroposterior view.

bination, was administered. At the follow-up visit 6 months after the surgery, the patient was in good health, without neurological signs or pain and without signs of mobilization of the implant. At the time of publication of this report, antibiotic therapy is still ongoing.
All procedures performed were in accordance with the 1964 Helsinki declaration. This research has been approved by the IRB of the authors' affiliated institutions. Written informed consent for scientific purposes and clinical data collection was obtained according to institutional protocol.

Literature review
After the screening of 444 titles and abstracts, 113 papers were considered eligible for the full-text analysis. Seventy-seven studies that met inclusion criteria were finally included in the review. Overall, including our report, 91 patients affected by NTMSD were analyzed in this systematic review [9-85]. More than 50 patients with post-surgical M. *xenopi* SD caused by the contamination of saline solution used during the surgery in a private hospital were excluded from our review due to the lack of individual patient clinical data [86].

Demographical data
The mean age of included patients was 50.9 (+/-18.2) years, 4 of these (4.4%) were pediatric (<18yo) while 28 (30.8%) of these were elderly (>65yo). Among the patients included 52 (57.2%) were male and 39 (42.8%) were females. Demographic and clinical data are summarized in Table 1.

Localization, presentation symptoms and underlying conditions
NTMSD involved the thoracic spine in 47 patients (51.7%), the lumbar spine in 39 cases (42.9%) and the cervical spine only in one patent (1.1%). In four patients (4.4%) there was involvement of the whole spine. A single level involvement was found in 63 patients (69.3%), multiple level involvement in 28 patients (30.7%) (including the four case of whole spine involvement). The presence of paraspinal abscesses associated with NTMSD were reported in 74 patients (81.4 %) cases: among these, 44 (59.4%) were paravertebral abscess, 14 (18.9%) were epidural abscess, 3 (4%) were intra-psoas abscess and 1 was retroperitoneal. In 12 cases (13.2%) there were multiple abscess localization. In 30 cases extraspinal localizations of NTM infections were described. The most frequent extraspinal localization was lungs in 7 cases (7.7%), pelvic ring in 7 cases (7.7%), shoulder in 4 cases (4.4%) and knee in 2 cases (2.2%). Multiple extraspinal localizations were described in 8 patients (8.8%). The most frequent presentation symptoms were the back pain in 82 (90.2%) patients followed by lower extremity weakness in 35 cases (38.5%), fever in 25 (27.5%) and weight loss in 11 (12.1%).
Forty patients (44%) of these review were immunocompromised, among these: 21 patients suffered of autoimmune diseases (SEL, polymyosite, sarcoidosis etc.) in treatment with immunosuppressive drugs (mainly steroids), 13 patients had HIV disease, 5 patients had congenital immunodeficiency (defect of the interferon-gamma receptor and chronic granulomatous disease), 1 patient was a kidney transplant recipient. The most frequently observed predisposing conditions in immunocompetent patients were: previous spine surgery or epidural injection in 10 cases (11%), previous tuberculous infections in 6 patients (6.6%), diabetes in 5 cases (5.5%) and intravenous drug abuse in 4 cases (4.4%).

Diagnosis and etiology
The biological material that led to the diagnosis was obtained in 48 cases (52.8%) from a percutaneous biopsy, in 32 cases (35.2%) from surgical material, in 5 cases (5.5%) from sputum, in 3 cases (3.3%) from the drainage of paraspinal abscesses, and in 3 (3.3%) cases from blood cultures. Etiological diagnosis was made by culturing samples in 69 cases, (75.9%), nucleic acid hybridization in 12 cases (13.3%) and polymerase chain reaction (PCR) in 10 cases. Among included studies only 13 of these reported the culture medium used for isolation of the pathogen (Lowenstein-Jensen in 9 cases, Middlebrook 7H10 in 3 cases and MacConkey in one case). In 29 cases the growth time of pathogen in culture medium and was reported. The mean growth time was 33.4 (+/-24.1) days
Isolated *Mycobacterium* species were: M. *avium complex* (MAC) in 22 cases (24.2%), M. *intracellulare* (a subtype of MAC) in 20 cases (22%), M. *xenopi* in 11 cases (12.1%), M. *fortuitum* in 7 cases (7.7%), M. *chelonae* in 7 (7.7%) cases, M. *abscessus* in 6 cases (6.6%), M. *kansasii* in 6 cases (6.6%), M. *chimaera* in 3 cases (3.3%), M. *simiae* in 2 cases (2.2%) and in one case (1.1%) M. *scrofulaceum*, M.

smegmatis, M. *malmoense*, M. *phlei*, M. *heckeshornense*, M. *flavescens*, M. *arosiense*. Of all the examined studies, the skin test with purified tuberculin antigen was reported in only 33 patients (36.3%); among these 10 (30.3%) were positive and 23 (69.7%) were negative.

Treatment options

Antibiotic therapy alone was administered in 43 patients (47.3%), while in 48 patients (52.7%) a combination of medical and surgical treatment was described. In 14 cases (29.4%) a posterior decompression was reported, in 9 cases (18.9%) abscess drainage, in 9 cases (18.9%) anterior and posterior decompression and fusion, in 8 cases (16.8%) posterior decompression and fusion. in 7 cases (14.7%) anterior decompression and fusion and in 1 case (2.1%) vertebroplasty with antibiotic cement. Combination antibiotic treatment was prescribed in all cases. The most used combination of drugs was Clarithromycin, Ethambutol, Rifampicin in 15 cases (16.5%) followed by isoniazid, ethambutol, rifampicin and pyrazinamide in 8 cases (8.8%). The most commonly used antibiotic was ethambutol (64.9%), followed by: rifampicin (61.6%), clarithromycin (51.7%), isoniazid (36.3%), pyrazinamide (25.3%), amikacin (15.4%), streptomycin (12.1%) and azithromycin (9.9%). In 53 (58.3%) cases the duration of antibiotic therapy was reported. The mean duration was 419 days (+/-325.8.9). In 12 cases (13.2%) antibiotic therapy was still ongoing at the time the case report was published.

Outcomes

The clinical outcome were reported in 80 cases (88%). Twenty-five patients (31.2%) had a complete recover at the last follow-up visit. In 39 patients (48.7%) there was an improvement in symptoms and radiological picture without complete recovery.

For eight patients (10%) the antibiotic therapy was not effective, thus the infection resulted uncured.

Eight patients (10%) died during follow-up from complications that occurred during antibiotic therapy or the post-operative course. A complication was reported in 30 patients (33%), among these, neurological sequelae were reported in 7 patients. Spine deformity were observed in 4 patients. Drug toxicity was observed only in 2 cases (2.2%), thus the pharmacological treatment was promptly changed. Superficial wound infection was reported in two cases. The recurrence rate of the infection was 13.2%.

DISCUSSION

NTMSDs represent a chronic disease, causing nonspecific symptoms, such as back pain, malaise, and fatigue which are unnoticed for long time [87]. The most common microorganism associated with SD is *Staphylococcus aureus* especially in the high-income countries. In low income countries, Spinal Tuberculosis (ST) is still a common cause of SD presenting with early disc space sparing and vertebral bodies destruction [88] while globally NTM spine infection are rarely described.

Many mycobacterial species were reported to be implicated in humans infections, including *M. haemophilum, M. kansasii, M. avium complex* (MAC), *M. asiaticum*, *M. flavescens*, *M. terrae*, *M. goodii* and *M. szulgai*; among these, *M. xenopi* is one of the leading causes of mycobacterial SD [88,89]. NTMSDs are often misdiagnosed as tuberculosis due to analogy in clinical presentation [32, 34]. Definitive diagnosis must be confirmed by cultural, molecular and histological examination of tissue sampled during surgery or percutaneous biopsy [66]. Blood cultures are often negative and up to 6 weeks of incubation are required to obtain positive cultures. A CT-guided fine-needle percutaneous biopsy, was considered the gold standard in most of the cases. Open biopsy should be preferred when surgical decompression of the spinal cord was necessary because of the presence of neurologic symptoms [86]. NTM, including *M. xenopi,* are organisms frequently found in water and soil and can inhabit body surfaces [52]. Generally, in the immunocompetent host, exposure to NTM does not lead to disease. Therefore, isolated cultures of NTM can often be considered colonizers or contaminants [85]. It may be difficult to discriminate between contamination and real infection. The most common clinical manifestation of NTM infection is lung disease. NTM bones, joints and skin infections are usually related to trauma, injury or contamination during surgical procedures. On the other hand NTMSDs are not usually associated to a trauma or penetrating injury [69]. *M. xenopi* and NTMSDs without apparent

trauma or surgery could presumably be due to haematogenous diffusion. They occur usually in immunocompromised patients; Indeed, in our review we found that 44% of patients presented an immunosuppression condition (iatrogen or disease related). Furthermore, 11% of total cases consist of immunocompetent patients who underwent spinal surgery before diagnosis. The rarity of NTMSDs, difficulties to reach a diagnosis and limited clinical experience represent nowadays a therapeutic challenge.

Conventional anti-tuberculous drugs are not effective for the treatment of NTMSDs and this issue underscores the importance of reaching a correct diagnosis as soon as possible [90]. Since several weeks are needed to obtain the result of mycobacteria culture it could be appropriate to perform PCR and culture for *M. tuberculosis* and NTM when clinical suspect is considered. Surgical treatment is mandatory for patients with neurologic deficit, uncontrolled infection, spinal instability, collapse of one or more vertebral bodies. [69, 91, 92]. Cortico-cancellous bone autograft with instrumented posterior fusion seems to give good clinical results [30, 93]. Usually antibiotic therapy consists in a long lasting combination of Clarithromycin, Ethambutol and Rifampin. Custom made antimycobacterial therapy is the main model to consider, however there is not general consensus on the effective duration of the treatment that should last at least 12 months based on clinical and radiographic pictures improvement (after 6-8 months of follow up) [94]. The 52.7% of patients needed a combined medical and surgical treatment.

In our case we opted for a combined approach abscess drainage with decompression and posterior spine fusion surgery was necessary because of neurological symptoms due to vertebral collapse. After cultural microbiological response, Rifabutin and Ethambutol antibiotic therapy was prescribed and it still ongoing at time of writing.

NTMSDs represents a rare condition, even though its incidence may be underestimated, due to diagnostic technical difficulties. This review highlights the rarity of spinal infections due to *NTM* and the difficulty of their management. We suggest that, when clinical suspicion of NTMSDs occur, as any for any SD, spinal MRI is mandatory to confirm diagnosis and to identify the possible presence of spinal abscess and consequently plan the biopsy, which should be studied with microbiological techniques mentioned above. The literature provides only a few studies regarding the potential usefulness of PET/CT as a diagnostic tool in spondylodiscitis, however, its potential role in functional assessment of inflammatory and infectious diseases including mycobacteria is gaining interest. The preliminary studies suggest a potential alternative role for PET/CT in the evolution, and follow-up assessment in patients in witch MRI was contraindicated [95].

The present study had some limitation. In fact all studies included are case report or case series with low level of evidence (IV-V). Due to challenging diagnosis, real NTMSD incidence could be underestimate, therefore, the results of this review should be taken with caution. Further clinical studies are needed for better investigating this challenging topic.

In conclusion, NTMSD are rare conditions and their real incidence could have been be underestimated due to diagnostic limits. When biological samples were obtained, molecular and cultural procedures were needed to identify MTB and NTM must be routinely investigated, especially in culture-negative spondylodiscitis, primarily in immunocompromised patients. Moreover, we suggest a tailored approach with prolonged antibiotic therapy for the treatment of NTM infections, eventually associated with surgery in selected cases.

Acknowledgments
AS and AP contributed equally.

Funding
None

Conflict of interest
Authors declare that they have no conflict of interest.

REFERENCES

[1] Skaf GS, Domloj NT, Fehlings MG, et al. Pyogenic spondylodiscitis: an overview. *J Infect Public Health.* 2010; 3 (1), 5-16.

[2] Perna A, Ricciardi L, Sturiale CL, et al. Skipped vertebral spontaneous spondylodiscitis caused by *Granulicatella adiacens*: Case report and a systematic literature review. *J Clin Orthop Trauma*. 2019; doi: 10.1016/j.jcot.2019.07.002

[3] Wayne LG, Sramek HA. Agents of newly recognized or infrequently encountered mycobacterial diseases. *Clin Microbiol Rev*. 1992; 5 (1), 1-25.
[4] Griffith DE, Aksamit T, Brown-Elliott BA, et al. An official ATS/IDSA statement: diagnosis, treatment, and prevention of nontuberculous mycobacterial diseases. *Am J Respir Crit Care Med.* 2007; 175 (4), 367-416.
[5] Weissman S, Parker RD, Siddiqui W, Dykema S, Horvath J. Vertebral osteomyelitis: retrospective review of 11 years of experience. *Scand J Infect Dis*. 2014; 46 (3), 193-9.
[6] Schwabacher H. A strain of Mycobacterium isolated from skin lesions of a cold-blooded animal, *Xenopus laevis,* and its relation to atypical acid-fast bacilli occurring in man. *J Hyg (Lond*). 1959; 57 (1), 57-67.
[7] Hoefsloot W, van Ingen J, Andrejak C, et al. The geographic diversity of nontuberculous mycobacteria isolated from pulmonary samples: an NTM-NET collaborative study. *Eur Respir J.* 2013; 42 (6),1604-13.
[8] Moher D, Shamseer L, Clarke M, et al. Preferred reporting items for systematic review and meta-analysis protocols (PRISMA-P) 2015 statement. *Syst Rev.* 2015; 4 (1), 1.
[9] Watanakunakorn C, Trott A. Vertebral osteomyelitis due to *Mycobacterium kansasii*. *Am Rev Respir Dis*. 1973; 107 (5), 846-50.
[10] Chusid MJ, Parrillo JE, Fauci AS. Chronic granulomatous disease. Diagnosis in a 27-year-old man with *Mycobacterium fortuitum*. *JAMA*. 1975; 233 (12), 1295-6.
[11] Smith ER. *Mycobacterium fortuitum* spinal infection: case report. *Pathology.* 1976; 8 (4), 289-92.
[12] Zvetina JR, Demos TC, Rubinstein H. Mycobacterium intracellulare infection of the shoulder and spine in a patient with steroid-treated systemic lupus erythematosus. *Skeletal Radiol*. 1982; 8 (2), 111-3.
[13] Rose HD, Dorff GJ, Lauwasser M, Sheth NK. Pulmonary and disseminated *Mycobacterium simiae* infection in humans. *Am Rev Respir Dis*. 1982; 126 (6), 1110-3.
[14] Prosser AJ. Spinal infection with *Mycobacterium xenopi*. *Tubercle.* 1986; 67 (3), 229-32.
[15] Brodkin H. Paraspinous abscess with *Mycobacterium avium-intracellulare* in a patient without AIDS. *South Med J*. 1991; 84 (11), 1385-6.
[16] Rahman MA, Phongsathorn V, Hughes T, Bielawska C. Spinal infection by *Mycobacterium xenopi* in a non-immunosuppressed patient. *Tuber Lung Dis*. 1992; 73 (6), 392-5.
[17] Pruitt TC, Hughes LO, Blasier RD, McCarthy RE, Glasier CM, Roloson GJ. Atypical mycobacterial vertebral osteomyelitis in a steroid-dependent adolescent. A case report. *Spine (Phila Pa 1976).* 1993; 18 (16), 2553-5.
[18] Pirofsky JG, Huang CT, Waites KB. Spinal osteomyelitis due to Mycobacterium avium-intracellulare in an elderly man with steroid-induced osteoporosis. *Spine* (Phila Pa 1976). 1993; 18 (13), 1926-9.
[19] Miller WC, Perkins MD, Richardson WJ, Sexton DJ. Pott's disease caused by *Mycobacterium xenopi:* case report and review. *Clin Infect Dis* 1994; 19 (6), 1024-8.
[20] Mahan S, Jolles PR. MAI osteomyelitis. 18-year scintigraphic follow-up. *Clin Nucl Med*. 1995; 20 (7), 594-8.
[21] Froideveaux D, Claudepierre P, Brugières P, Larget-Piet B, Chevalier X. Iatrogenically induced spondylodiskitis due to Mycobacterium xenopi in an immunocompetent patient. *Clin Infect Dis.* 1996; 22 (4), 723-4.
[22] Telgt DS, van den Hoogen FH, Meis JF, Lemmens JA, van de Putte LB. Arthritis and spondylodiscitis caused by *Mycobacterium xenopi* in a patient with systemic lupus erythematosus. *Br J Rheumatol.* 1997; 36 (9), 1025-6.
[23] Igram CM, Petrie SG, Harris MB. Atypical mycobacterial vertebral osteomyelitis in an immunocompetent patient. *Orthopedics.* 1997; 20 (2), 163-6.
[24] Sarria JC, Chutkan NB, Figueroa JE, Hull A. Atypical mycobacterial vertebral osteomyelitis: case report and review. *Clin Infect Dis.* 1998; 26 (2), 503-5.
[25] Weiner BK, Love TW, Fraser RD. *Mycobacterium avium intracellulare*: vertebral osteomyelitis. *J Spinal Disord*. 1998; 11 (1), 89-91.
[26] O'Brien DP, Rawluk DJ. Iatrogenic Mycobacterium infection after an epidural injection. *Spine (Phila Pa 1976).* 1999; 24 (12), 1257-9.
[27] Erard P, Robert-Grandpierre F, Kaeser P. Vertebral osteomyelitis caused by *Mycobacterium avium-intracellulare* in a patient with AIDS. *Clin Microbiol Infect*. 1999; 5 (10), 643-4.
[28] King BF. Disseminated *Mycobacterium avium complex* in an immunocompetent previously healthy woman. *J Am Board Fam Pract*. 1994; 7 (2), 145-8.
[29] Rotstein AH, Stuckey SL. *Mycobacterium avium complex* spinal epidural abscess in an HIV patient. *Australas Radiol*. 1999; 43 (4), 554-7.
[30] Danesh-Clough T, Theis JC, van der Linden A. *Mycobacterium xenopi* infection of the spine: a case report and literature review. *Spine (Phila Pa 1976).* 2000; 25 (5), 626-8.
[31] Nalaboff KM, Rozenshtein A, Kaplan MH. Imaging of Mycobacterium avium-intracellulare infection in AIDS patients on highly active antiretroviral therapy: reversal syndrome. *AJR Am J Roentgenol.* 2000; 175 (2), 387-90.
[32] Chan ED, Kong PM, Fennelly K, Dwyer AP, Iseman MD. Vertebral osteomyelitis due to infection with nontuberculous Mycobacterium species after blunt trauma to the back: 3 examples of the principle of locus minoris resistentiae. *Clin Infect Dis.* 2001; 32 (10), 1506-10.
[33] Kulasegaram R, Richardson D, Macrae B, de Ruiter A. *Mycobacterium xenopi* osteomyelitis in a patient on highly active antiretroviral therapy (HAART). *Int J STD AIDS*. 2001; 12 (6), 404-6.
[34] Suttner NJ, Adhami Z, Aspoas AR. *Mycobacterium chelonae* lumbar spinal infection. *Br J Neurosurg*. 2001; 15 (3), 265-9.

[35] White VL, Al-Shahi R, Gamble E, Brown P, Davison AG. Transverse myelopathy and radiculomyelopathy associated with pulmonary atypical Mycobacterium infections. *Thorax.* 2001; 56 (2), 158-60.
[36] Arend SM, Janssen R, Gosen JJ et al. Multifocal osteomyelitis caused by nontuberculous mycobacteria in patients with a genetic defect of the interferon-gamma receptor. *Neth J Med.* 2001; 59 (3), 140-51.
[37] Otaki Y, Nakanishi T, Nanami M et al. A rare combination of sites of involvement by *Mycobacterium intracellulare* in a hemodialysis patient: multifocal synovitis, spondylitis, and multiple skin lesions. *Nephron.* 2002; 92 (3), 730-4.
[38] Niazi S, Batra V, Zangrilli JG. Atypical mycobacterial osteomyelitis in a non-AIDS patient. *Conn Med*. 2002; 66 (7), 387-9.
[39] Aberg JA, Williams PL, Liu T, et al. AIDS Clinical Trial Group 393 Study Team. A study of discontinuing maintenance therapy in human immunodeficiency virus-infected subjects with disseminated *Mycobacterium avium complex*: AIDS Clinical Trial Group 393 Study Team. *J Infect Dis.* 2003; 187 (7), 1046-52.
[40]. Mehta JB, Emery MW, Girish M, Byrd RP Jr, Roy TM. Atypical Pott's disease: localized infection of the thoracic spine due to *Mycobacterium avium-intracellulare* in a patient without human immunodeficiency virus infection. *South Med J*. 2003; 96 (7), 685-8.
[41] Mastroianni A. *Mycobacterium flavescens* vertebral osteomyelitis in an immunocompetent host. *Infez Med*. 2003; 11 (2), 97-101.
[42] Yamashita T, Endo T, Hamamoto Y, Akiba H, Ono I, Jimbow K. A case of systemic osteomyelitides due to *Mycobacterium avium*. *J Dermatol.* 2004; 31 (12), 1036-40.
[43] Yano T, Okuda S, Kato K, Kato K, Kishimoto T. *Mycobacterium kansasii* osteomyelitis in a patient with AIDS on highly active antiretroviral therapy. *Intern Med*. 2004; 43 (11), 1084-6.
[44] Meybeck A, Fortin C, Abgrall S et al. Spondylitis due to *Mycobacterium xenopi* in a human immunodeficiency virus type 1-infected patient: case report and review of the literature. *J Clin Microbiol.* 2005; 43 (3), 1465-6.
[45] Tsai CW, Wang JT, Tsai CC, Yeh KH. Disseminated *Mycobacterium kansasii* infection in an HIV-negative patient presenting with mimicking multiple bone metastases. *Diagn Microbiol Infect Dis*. 2006; 54 (3), 211-6.
[46] Corrales-Medina V, Symes S, Valdivia-Arenas M, Boulanger C. Localized *Mycobacterium avium complex* infection of vertebral and paravertebral structures in an HIV patient on highly active antiretroviral therapy. *South Med J.* 2006; 99 (2), 174-7.
[47] Danaviah S, Govender S, Gordon ML, Cassol S. Atypical mycobacterial spondylitis in HIV-negative patients identified by genotyping. *J Bone Joint Surg Br.* 2007; 89 (3), 346-8.
[48] Korres DS, Papagelopoulos PJ, Zahos KA, Kolia MD, Poulakou GG, Falagas ME. Multifocal spinal and extra-spinal *Mycobacterium chelonae* osteomyelitis in a renal transplant recipient. *Transpl Infect Dis*. 2007; 9 (1), 62-5.
[49] Hirakawa A, Miyamoto K, Ohno Y et al. Two-stage (posterior and anterior) surgical treatment of spinal osteomyelitis due to atypical mycobacteria and associated thoracolumbar kyphoscoliosis in a non-immunocompromised patient. *Spine (Phila Pa 1976).* 2008; 33 (7), E221-4.
[50] Metta H, Corti M, Brunzini R. Disseminated infection due to *Mycobacterium chelonae* with scleritis, spondylodiscitis and spinal epidural abscess. *Braz J Infect Dis.* 2008; 12 (3), 260-2.
[51] Sobottke R, Zarghooni K, Seifert H, et al. Spondylodiscitis caused by *Mycobacterium xenopi. Arch Orthop Trauma Surg*. 2008; 128 (10), 1047-53.
[52] Wong NM, Sun LK, Lau PY. Spinal infection caused by *Mycobacterium avium complex* in a patient with no acquired immune deficiency syndrome: a case report. *J Orthop Surg (Hong Kong).* 2008; 16 (3), 359-63.
[53] Rahman I, Bhatt H, Chillag S, Duffus W. *Mycobacterium chelonae* vertebral osteomyelitis. *South Med J*. 2009; 102 (11), 1167-9.
[54] Bhatia K, Frydenberg E, Steel T, Ow-Yang M. An anterior expandable titanium cage in Mycobacterium avium vertebral osteomyelitis. *J Clin Neurosci*. 2011; 18 (3), 431-4.
[55] Kim SH, Son DW, Lee SW, Song GS. An unusual case of post-operative spondylitis caused by mycobacterium intracellulare in an immunosuppressed patient. *J Korean Neurosurg Soc.* 2011; 50 (5), 460-3.
[56] Duttaroy B, Agrawal C, Pendse A. Spinal tuberculosis due to dissemination of atypical mycobacteria. *Indian J Med Sci.* 2004; 58 (5), 203-5.
[57] FA Zimba. *MycobacteriumsSmegmatis* infection of a lumbar spine instrumented fusion. *Am J Infect Dis.* 2011; 7 (1), 24-27.
[58] Suzuki T, Murai H, Miyakoshi N, Hongo M, Itoi E, Shimada Y. Osteomyelitis of the spine caused by *Mycobacterium avium complex* in an immunocompetent patient. *J Orthop Sci.* 2013; 18 (3), 490-5.
[59] Bartanusz V, Savage JG. Destructive *Mycobacterium simiae* infection of the lumbar spine and retroperitoneum in an immunocompetent adult. *Spine* J. 2012; 12 (6), 534-5.
[60] Hashizume Y, Takise A, Shimizu Y. Disseminated *Mycobacterium avium complex* infection in a compromised host. *Intern Med.* 2012; 51 (13), 1809-10.
[61] Salmon JH, Direz G, Ziza JM, Desplaces N, Brochot P, Eschard JP. Discitis and sacroiliitis diagnosed 15 years after iatrogenic *Mycobacterium xenopi* inoculation. *Joint Bone Spine*. 2012; 79 (4), 409-11.
[62] Wang CS, Feng SW, Huang LJ et al. Atypical mycobacterial spondylitis as a challenging differential diagnosis to metastatic disease of the spine: a case report. *Eur J Orthop Surg Traumatol*. 2013; 23 (2), S135-9.

[63] Garcia DC, Sandoval-Sus J, Razzaq K, Young L. Vertebral osteomyelitis caused by *Mycobacterium abscessus*. *BMJ Case Rep*. 2013; doi: 10.1136/bcr-2013-009597.
[64] Longardner K, Allen A, Ramgopal M. Spinal osteomyelitis due to *Mycobacterium fortuitum* in a former intravenous drug user. *BMJ Case Rep*. 2013; doi: 10.1136/bcr-2013-010326.
[65] Matt L, Calvey C, Muakkassa K, Speakman E, Haller NA, Watkins D. A rare case of atypical mycobacterium -associated spinal cord compression in an HIV-aids patient. *Infect Dis Clin Pract* 2013; 21, 196-200.
[66] Shimizu H, Mizuno Y, Nakamura I, Fukushima S, Endo K, Matsumoto T. Vertebral osteomyelitis caused by non-tuberculous mycobacteria: case reports and review. *J Infect Chemother.* 2013; 19 (5), 972-7.
[67] Bakhsh WR, Mesfin A. *Mycobacterium kansasii* infection of the spine in a patient with sarcoidosis: a case report and literature review. *J Surg Orthop Adv*. 2014; 23 (3), 162-5.
[68] Blair PW, Herrin D, Abaalkhail N, Fiser W. DRESS syndrome presenting after initiation of *Mycobacterium avium complex* osteomyelitis treatment. *BMJ Case Rep.* 2015; doi: 10.1136/bcr-2015-210907.
[69] Kim CJ, Kim UJ, Kim HB, et al. Vertebral osteomyelitis caused by non-tuberculous mycobacteria: Predisposing conditions and clinical characteristics of six cases and a review of 63 cases in the literature. *Infect Dis (Lond*). 2016; 48 (7), 509-16.
[70] Stjepanovic MI, Pesut DP, Lesic AR, Stevic RS. Pulmonary and vertebral *Mycobacterium avium* disease in a HIV-negative 71-year-old man - A Case Report. *Infez Med*. 2016; 24 (4), 345-8.
[71] Biswas SN, Chakraborty PP, Satpathi PS, Patra S. Atypical presentation of atypical mycobacteria in atypical diabetes. *Oxf Med Case Reports*. 2016; 2016 (4), 101-4.
[72] Kumar M, Verma S, Dhole TN, Kumar R. Non-tuberculous mycobacteria mimic of MDR-TB infection in Pott's disease. *BMJ Case Rep*. 2016; doi: 10.1136/bcr-2016-215265.
[73] Naik R, Cortes JA. Persistent Mycobacterium abscessus infection secondary to interferon-γ autoantibodies. *Ann Allergy Asthma Immunol.* 2016; 116 (5), 461-2.
[74] Chiesi S, Piacentini D, Salerno ND, et al. Disseminated Mycobacterium chimaera infection after open heart surgery in an Italian woman: a case report and a review of the literature. *Infez Med.* 2017; 25 (3), 267-9.
[75] Moutsoglou DM, Merritt F, Cumbler E. Disseminated *Mycobacterium chimaera* presenting as vertebral osteomyelitis. *Case Rep Infect Dis.* 2017; doi: 10.1155/2017/9893743.
[76] Takemoto Y, Tokuyasu H, Ikeuchi Tet al. Disseminated *Mycobacterium scrofulaceum* infection in an immunocompetent host. *Intern Med*. 2017; 56 (14), 1931-5.
[77] Gerogianni I, Boutlas S, Karachalios T, Petinaki E, Vlychou M, Gourgoulianis KI. A *M. avium complex* spondylodiscitis in a middle-aged woman with diabetes. *Respir Med Case Rep.* 2017; 21, 71-3.
[78] Douiri N, Lefebvre N, Hansmann Y, Partisani M, Schramm F. Relapsing Pott disease caused by *Mycobacterium heckeshornense* in a well-controlled HIV-infected patient. *Med Mal Infect*. 2018; 48 (2), 157-8.
[79] Gray ME, Liu PW, Wispelwey B. *Mycobacterium Avium complex* vertebral osteomyelitis in the absence of HIV infection: a case report and review. *BMC Infect Dis.* 2018; 18 (1), 235.
[80] Marino A, Caltabiano E, Zagami A et al. Rapid emergence of cryptococcal fungemia, *Mycobacterium chelonae* vertebral osteomyelitis and gastro intestinal stromal tumor in a young HIV late presenter: a case report. *BMC Infect Dis*. 2018; 18 (1), 693.
[81] Rudikoff AG, Ganocy TK 2nd, Kansagra K, Torres FA, Humphries BD, Hernandez Conte A. Thoracolumbar osteomyelitis secondary to systemic mycobacterium chimaera infection status post aortic valve replacement. *J Cardiothorac Vasc Anesth*. 2019; 33 (6), 1704-9.
[82] Bang D, Rasmussen EM, Andersen AB. Mycobacterium arosiense, an unexpected cause of osteomyelitis in a patient with sarcoidosis: a case report. *BMC Infect Dis*. 2019; 19 (1), 994.
[83] Kadota N, Shinohara T, Hino H, et al. Mycobacterium abscessus ssp. abscessus infection progressing to empyema from vertebral osteomyelitis in an immunocompetent patient without pulmonary disease: a case report. *BMC Pulm Med*. 2019; 19 (1), 100.
[84] McGee AW Jr, Dean CS, Ignatiuk A, Savelli C, Kleck CJ. Mycobacterium phlei Vertebral Osteomyelitis. *J Am Acad Orthop Surg Glob Res Rev.* 2019; 3 (12), e18.00069.
[85] Moral MZ, Desai K, Arain AR, O'Leary RE, Haddad SF, Lawrence JP. Mycobacterium abscessus-associated vertebral osteomyelitis in an immunocompetent patient: a rare case report and literature review. *Spinal Cord Ser Cases*. 2019; 5, 53.
[86] Astagneau P, Desplaces N, Vincent V, et al. Mycobacterium xenopi spinal infections after discovertebral surgery: investigation and screening of a large outbreak. *Lancet.* 2001; 358 (9283), 747-51.
[87] Ambrose GB, Alpert M, Neer CS. Vertebral osteomyelitis: a diagnostic problem. *JAMA.* 1966; 197 (8), 619-22.
[88] Tortoli E. Clinical manifestations of nontuberculous mycobacteria infections. *Clin Microbiol Infect.* 2009; 15 (10), 906-10.
[89] Brown-Elliot BA, Nash KA, Wallace RJ Jr. Antimicrobial susceptibility testing, drug resistance mechanisms, and therapy of infections with nontuberculous mycobacteria. *Clin Microbiol Rev.* 2012; 25 (3), 545-82.
[90] Alfandari S. Recommandations du C-CLIN Paris Nord pour le diagnostic et le traitement des infections ostéo-articulaires à *Mycobacterium xenopi. Méd Mal Infect*. 1998; 28, 231-4.
[91] Tamburrelli FC, Perna A, Proietti L, Zirio G, San-

tagada DA, Genitiempo M. The feasibility of long-segment fluoroscopy-guided percutaneous thoracic spine pedicle screw fixation, and the outcome at two-year follow-up. *Malays Orthop J*. 2019; 13 (3), 39-44.
[92] Proietti L, Ricciardi L, Noia G, et al. Extensive spinal epidural abscesses resolved with minimally invasive surgery: two case reports and review of the recent literature. *Acta Neurochir* Suppl. 2019; 125, 345-53.
[93] De Vitis R, Passiatore M, Perna A, Tulli A, Pagliei A, Taccardo G. Modified Matti-Russe technique using a "butterfly bone graft" for treatment of scaphoid non-union. *J Orthop.* 2019; 19: 63-6.
[94] Griffith D, Aksamit T, Brown-Elliott BA et al. An official ATS/IDSA statement: diagnosis, treatment, and prevention of nontuberculous mycobacterial diseases. *Am J Respir Crit Care Med.* 2007; 175 (7), 744-5.
[95] Altini C, Lavelli V, Niccoli-Asabella A, et al. Comparison of the Diagnostic Value of MRI and Whole Body 18F-FDG PET/CT in Diagnosis of Spondylodiscitis. *J Clin Med*. 2020; 9 (5), 1581.